

## Olecranon Bone Graft: Revisited

Berkan Mersa, MD,\* Ismail Bulent Ozcelik, MD,\* Fatih Kabakas, MD,\*  
Bulent Sacak, MD,\* and Atakan Aydin, MD†

**Abstract:** Autogenous bone grafts are frequently in use in the field of reconstructive upper extremity surgery. Cancellous bone grafts are applied to traumatic osseous defects, nonunions, defects after the resection of benign bone tumors, arthrodesis, and osteotomy procedures. Cancellous bone grafts do not only have benefits such as rapid revascularization, but they also have mechanical advantages. Despite the proximity to the primary surgical field, cancellous olecranon grafts have not gained the popularity they deserve in the field of reconstructive hand surgery. In this study, the properties, advantages, and technical details of harvesting cancellous olecranon grafts are discussed.

**Key Words:** olecranon, bone grafts, hand reconstruction

(*Tech Hand Surg* 2010;14: 196–199)

Autogenous bone grafts are widely used in the field of reconstructive hand surgery. Several donor sites are defined and used. Introduction of olecranon grafts is relatively new compared with the ilium, tibia, fibula, and cranial grafts, which were the first to be defined.<sup>1–3</sup>

Bone autografts may be either cancellous or cortical. Cancellous autografts provide the trabecular bone lined with osteoblasts providing for osteogenesis under the influence of local cytokines and growth factors. These grafts are vascularized and incorporated quickly, and the low oxygen content of the graft, as it is incorporated, attracts host stem cells to the graft site. Cancellous autografts lack significant structural qualities.

Cortical autografts are rarely used because of donor site morbidity. When used, they provide structural support and supply osteoblasts, although significantly fewer than cancellous autografts. In contrast to the cancellous autograft, incorporation is initiated by osteoclasts that must reabsorb the dense cortical structure before allowing accelerated revascularization.

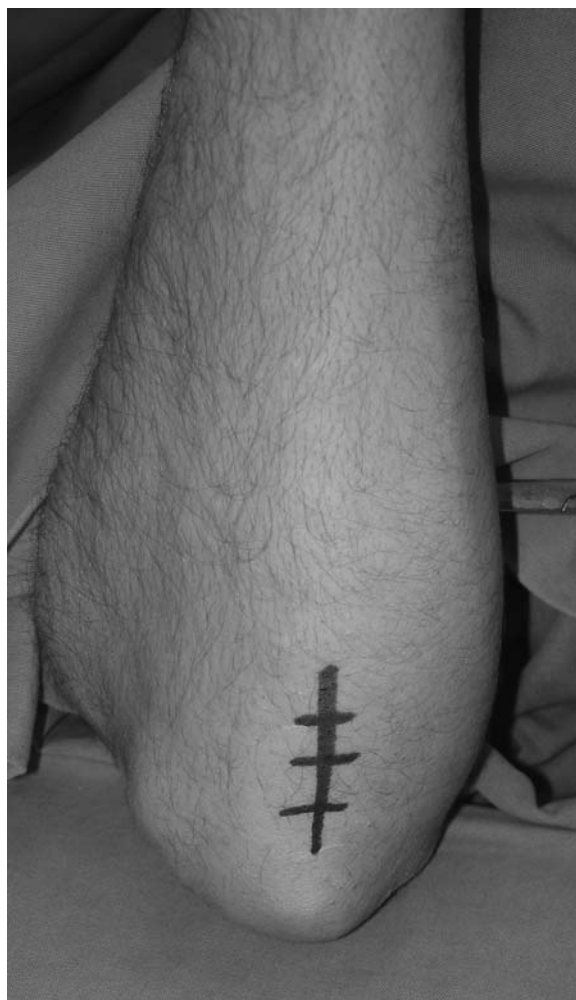Gallie and Robertson clearly presented that cancellous bone grafts had a better ratio of success compared with cortical bone grafts. They also pointed out the importance of periosteum over the donor site in terms of revascularization. Their result was attributed to the porous structure of cancellous grafts, which facilitated the osteoblast survival through increased infusion. Further studies in the subsequent years showed the promotion of growth factors inducing cellular growth and differentiation after bone grafting.<sup>4–6</sup>

Despite the lack of popularity, olecranon bone grafts are easily obtained, leave minimal donor site morbidity, and

provide versatility with superior structural properties. We report our clinical experience with olecranon bone grafts.

### SURGICAL TECHNIQUE

The procedures were performed under axillary block anesthesia and pneumatic arm tourniquet. The patient is placed in a supine position and the upper extremity is abducted as in regular hand surgery procedures. For bone graft harvesting, a bolster is placed under the arm, and the elbow is flexed over 90 degrees to provide adequate exposure to the surgical field. A longitudinal 3 to 4 cm incision is applied over the olecranon region (Fig. 1). As the only soft tissue over the bone is the origin of the deep flexor group posteromedially, simple dividing of the muscle provides adequate exposure. Opposing

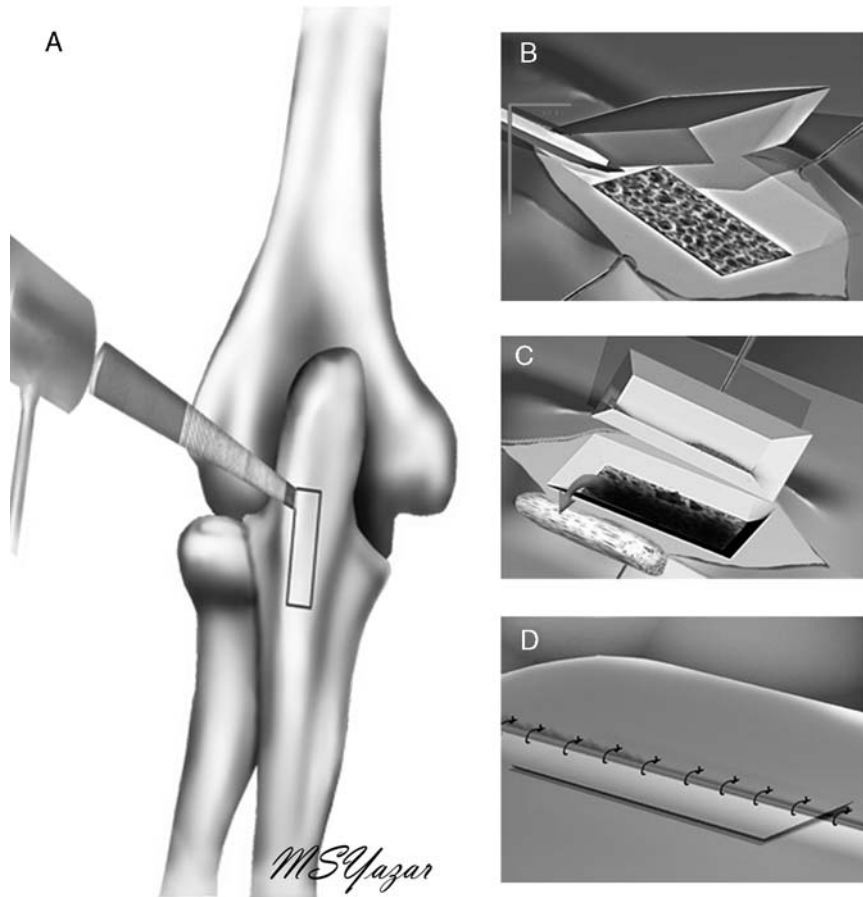


**FIGURE 1.** Three to 4 cm incision over the olecranon.

From the \*IST-EL Hand Surgery, Microsurgery and Rehabilitation Group, Gaziosmanpasa; and †Department of Plastic and Reconstructive Surgery, Istanbul Faculty of Medicine, Istanbul University, Capa, Istanbul, Turkey. Address correspondence and reprint requests to Bulent Sacak, MD, 19

Mayis Mahallesi Celal Atik Sokak 8B/21, Sisli, Istanbul. E-mail: bsacak@gmail.com.

Copyright © 2010 by Lippincott Williams & Wilkins



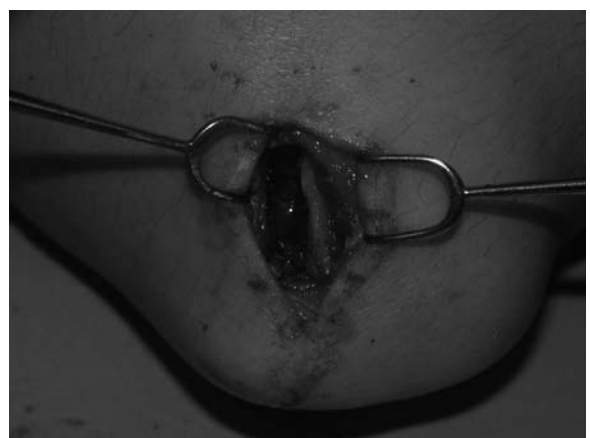**FIGURE 2.** Schematic diagram of the procedure. A fenestra is opened over the olecranon (A) in an oblique manner (B). Requested amount of the graft is harvested through the fenestrae (C). Periosteal sutures provide the stability of the replaced cortical bone cap (D).

periosteal flaps are elevated to both sides, and then a cortical bone fenestra with a width of 1 cm and length of 1 to 4 cm depending on the required amount is taken out with the help of either an oscillating saw or osteotome (Figs. 2, 3). Taking the

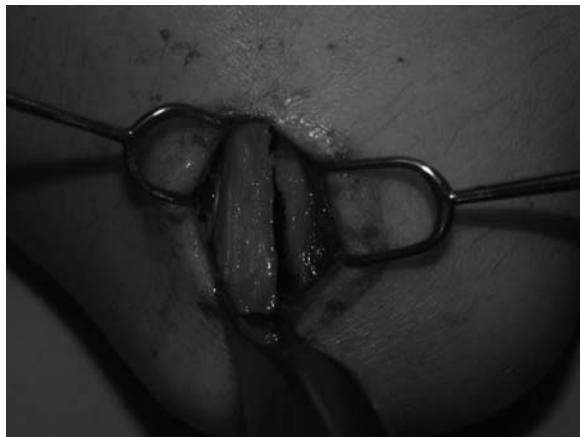cortical bone out in an angled manner does not only facilitate repositioning after the cancellous bone graft is harvested, but it also increases the cortical contact surface, thus possibly decreasing the healing time. A cancellous bone graft can be safely harvested through the fenestra, with a depth of 1 cm (Fig. 4). After the harvest, the cortical cap is returned to the original location (Fig. 5). Suturing of the periosteal flaps



**FIGURE 3.** The view of the cortical fenestra and the harvested cancellous bone graft.



**FIGURE 4.** Appearance of the donor site before the cortical cap is replaced back to its place.



**FIGURE 5.** The cortical bone cap is replaced.

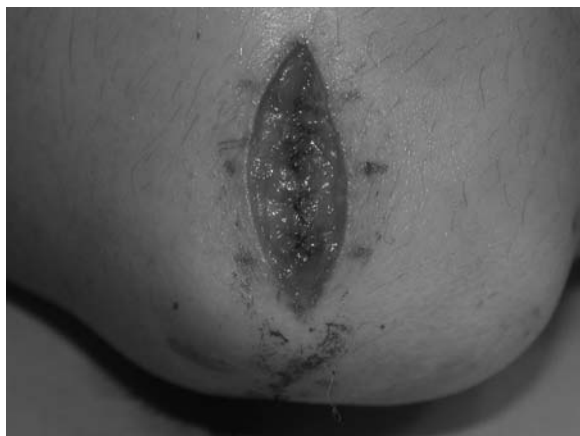with an absorbable suture helps to stabilize the cortical bone (Fig. 6). No drains are applied and skin is closed with either absorbable or nonabsorbable material.

### MATERIALS AND METHODS

From 2005 to 2009, we treated 48 patients with olecranon bone grafts in our department. The patients' ages ranged from 18 to 52 years (mean: 32 y). Thirty-six patients were male and 12 were female. Twelve patients were diagnosed with distal phalanx pseudoarthrosis, 3 patients with phalanx pseudoarthrosis, 3 patients with scaphoid pseudoarthrosis, 4 patients with traumatic metacarpal osseous defects, 7 patients with osseous defects after curettage for enchondroma, and 6, 4, and 1 patients, respectively for arthrodesis of proximal interphalangeal, distal interphalangeal, and carpometacarpal joints.

At a mean of 19 months follow-up (range: 4-46 mo), all the patients had healed well with a single complication of hematoma formation requiring drainage. No permanent sensitivity or pain was noted over the donor site.

One of the patients underwent surgery for a different metacarpal osseous defect in the same hand after trauma, 11 months after the initial surgery. Exploration of the former donor olecranon site displayed adequate healing and sufficient reserve for a secondary regrafting procedure.



**FIGURE 6.** Suturing of the periosteal flaps.

### DISCUSSION

Autogenous bone grafts have been used widely in the field of reconstructive hand surgery. Even though cortical osseous grafts are favored for the long bone defects of the hand, cancellous grafts are more rapidly vascularized, and progressive ossification rapidly restores the mechanical strength required. Most of the traumatic defects, fractures, nonunions, benign tumors, arthrodesis, and osteotomy cases are convenient for possible osseous grafting.

The iliac bone has traditionally been the first choice as the donor site for bone harvesting. Yet, the need for general anesthesia, prolonged hospitalization time, and possible complications such as meralgia paresthetica, hematoma, infection, chronic postoperative pain, peritoneal perforation, urethral injury, hernia, and arterial injury restricts its use in hand surgery in which only small amounts of cancellous bone graft are required.<sup>7-9</sup> In a recent study by Kim et al<sup>10</sup> the measured complication rates of an iliac bone harvest were higher than those thought earlier, such as a 16.5% rate of persistent pain greater than the primary surgical field and a 15% rate of difficulty in walking after 1 year.

Other donor site alternatives for harvesting small amounts of cancellous bone under axillary block are distal radius and lateral epicondyl.<sup>11-15</sup> Particularly, the distal radius has been popular in hand surgeries. Complication rates for harvesting bone grafts over the distal radius are as low as 1.7%. The most commonly reported complications are sensitivity, stenosing tenosynovitis of De Quervain, and superficial radial nerve injury.<sup>12</sup> Charles and Louis<sup>11</sup> have reported a series of 5 patients treated with cancellous bone grafts harvested from the lateral epicondyl. McGrath and Watson<sup>16</sup> reported a series of 124 patients treated with bone grafts without any complications. In their series, the distal radius was chosen as the donor site in 78 cases, proximal ulna in 19 cases, and metacarpal and phalangeal regions in 27 cases. Ozelcik et al<sup>17</sup> reported the successful use of cancellous olecranon grafts for treating nonunion of distal phalangeal fractures in 11 cases.

In the literature, olecranon bone grafts are rather shaped as chips, scraped through a cortical fenestra. In this study, harvested olecranon grafts are used as either solid blocks to fill the longitudinal defects of the phalangeal and metacarpal defects or as chips to fill amorphous defects.

The olecranon donor site has a clear margin to any major neurovascular structures. The ulnar nerve, which is the closest to the surgical field, is sufficiently far off from the surgical field and practically there is no risk for any nerve injury. As the incision is placed no less than 1.5 cm distal to the tip of the olecranon, the final scar is adequately distal to the elbow and forearm contact surfaces. In our series, we have not encountered any complaints regarding chronic pain or sensitivity over the donor site. Periosteal flaps, sutured over the replaced cortical window, reduce the risk of a hematoma formation. Yet, effective hemostasis should be provided to prevent any hematoma because of subcutaneous venous bleeding. In our series, one single case presented a hematoma requiring intervention. The quantity and quality of the cancellous bone graft is positively related with being in a nonosteoporotic state. Elder and osteoporotic patients may be excluded for an olecranon bone harvest. Harvesting cancellous bone grafts from an elder osteoporotic patient may lead to the pathologic olecranon fractures, which is one of the most undesired complications of this procedure. Walker and Meals<sup>18</sup> reported 2 cases of pathologic fractures in elderly male patients, at the age of 63 and 66. In our series, we have not encountered any iatrogenic or secondary olecranon fractures.

Eventually, the olecranon bone grafts that we have described in this study can be assessed as a good option to the conventional grafts, wherein the advantages can be listed as follows:

1. Particularly for hand surgery, axillary block is sufficient and endotracheal intubation is unnecessary.
2. The cortical bone segment is replaced back to its place, without any fixation devices. Periosteal repair prevents any contour deformities and provides a rapid healing.
3. There are no vital structures, such as nerves or arteries, in the periphery.
4. Periosteal repair and the replaced cortical bone segment prevent any hematoma formation with the reabsorption capacity of interosseous circulation.
5. Donor site scarring heals relatively well and is located at a less conspicuous region.
6. No plaster casts or splints are required. Simple shoulder arm brace, which is anyhow applied after most of the hand surgery cases, would be adequate in the follow-up.

### CONCLUSIONS

Even though the olecranon cancellous bone graft is not popularized and widely used, it is appropriate for most of the hand surgery cases indicating bone grafts. Olecranon, as a donor site, provides vast amounts of cancellous grafts and is proven to be clinically safe.

### REFERENCES

1. Hodgkinson DJ. The olecranon bone graft for nasal augmentation. *Aesthetic Plast Surg.* 1992;16:129–132.
2. Kirk NT. Non-union and bone grafts. *J Bone Joint Surg.* 1938;20:621–626.
3. Brutus JP, Loftus JB. Gerdy's tubercle as a source of cancellous bone graft for surgery of the upper extremity: description of technique. *J Hand Surg Am.* 2006;31:147–149.
4. Albee FA. *Bone Graft Surgery.* Philadelphia: WB Saunders; 1915.
5. Habal MB. Bone grafts. In: Goldwyn RM, Cohen MN, eds. *The Unfavorable Result in Plastic Surgery: Avoidance and Treatment.* 3rd ed. Philadelphia: Lippincott Williams & Wilkins; 2001:119–128.
6. Mehrara BJ, McCarty JG. Repair and grafting of bone. In: Mathes SJ, ed. *Plastic Surgery, Vol 1.* 2nd ed. Philadelphia: Saunders-Elsevier; 2006:639–718.
7. Goulet JA, Senunas LE, DeSilva GL, et al. Autogenous iliac crest bone graft. Complications and functional assessment. *Clin Orthop Relat Res.* 1997;339:76–81.
8. Fowler BL, Dall BE, Rowe DE. Complications associated with harvesting autogenous iliac bone graft. *Am J Orthop.* 1995;24:895–903.
9. Laurie SW, Kaban LB, Mulliken JB, et al. Donor-site morbidity after harvesting rib and iliac bone. *Plast Reconstr Surg.* 1984;73:933–938.
10. Kim DH, Rhim R, Li L, et al. Prospective study of iliac crest bone graft harvest site pain and morbidity. *Spine J.* 2009;9:886–892.
11. Charles LM, Louis DS. The lateral epicondyle as a bone graft donor site in procedures about the elbow. *J Hand Surg Am.* 1997;22:547–549.
12. Patel JC, Watson K, Joseph E, et al. Long-term complications of distal radius bone grafts. *J Handsurg Am.* 2003;28:784–788.
13. Biddulph SL. Bone donor site. Iliac crest or distal radius? *J Hand Surg Br.* 1999;24:645–646.
14. Mirly HL, Manske PR, Szerzinski JM. Distal anterior radius bone graft in surgery of the hand and wrist. *J Hand Surg Am.* 1995;20:623–627.
15. Bruno RJ, Cohen MS, Berzins A, Sumner DR. Bone graft harvesting from the distal radius, olecranon, and iliac crest: a quantitative analysis. *J Hand Surg Am.* 2001;26:135–141.
16. McGrath MH, Watson HK. Late results with local bone graft donor sites in hand surgery. *J Hand Surg Am.* 1981;6:234–237.
17. Ozçelik IB, Kabakas F, Mersa B, et al. Treatment of nonunions of the distal phalanx with olecranon bone graft. *J Hand Surg Eur.* 2009;34:638–642.
18. Walker LG, Meals RA. Pathologic fracture of the proximal ulna through a bone graft donor site. *J Hand Surg Am.* 1990;15:781–784.