

Journal of Hand Surgery (European Volume)

<http://jhs.sagepub.com>

Treatment of nonunions of the distal phalanx with olecranon bone graft

I. B. ÖZÇELİK, F. KABAKAS, B. MERSA, H. PURISA, I. SEZER and E. ERTÜNER

Journal of Hand Surgery (European Volume) 2009; 34; 638 originally published online Jul 8, 2009;

DOI: 10.1177/1753193409104494

The online version of this article can be found at:
<http://jhs.sagepub.com/cgi/content/abstract/34/5/638>

Published by:



<http://www.sagepublications.com>

On behalf of:



British Society for Surgery of the Hand



Federation of the European Societies for Surgery of the Hand

Additional services and information for *Journal of Hand Surgery (European Volume)* can be found at:

Email Alerts: <http://jhs.sagepub.com/cgi/alerts>

Subscriptions: <http://jhs.sagepub.com/subscriptions>

Reprints: <http://www.sagepub.com/journalsReprints.nav>

Permissions: <http://www.sagepub.co.uk/journalsPermissions.nav>

TREATMENT OF NONUNIONS OF THE DISTAL PHALANX WITH OLECRANON BONE GRAFT

İ. B. ÖZÇELİK, F. KABAKAS, B. MERSA, H. PURISA, İ. SEZER and E. ERTÜNER

From the İST-El Hand Surgery, Microsurgery, and Rehabilitation Group, TEM Hospital Hand Surgery Department – Gaziosmanpaşa Hospital Hand Surgery Department, Istanbul, Turkey

Distal phalangeal fractures are the most common fractures of the hand but nonunions are unusual in the distal phalanx. Eleven patients were operated on for nonunions of the distal phalanx. The diagnosis of nonunion was made by the presence of the clinical (pain, deformity, instability) and radiological signs of nonunion more than 4 months after the initial injury. Three patients had developed infection and four of them had bone resorption after their initial treatments, which probably caused nonunion. Olecranon bone grafting combined with Kirschner wire fixation was done in all patients. The mean follow up was 7 months (range 5–18 months). There were no major complications at the donor or recipient sites. One patient had a haematoma formation at the donor site. There was complete radiological union of bone-grafted sites in all patients except one. There were no cases of pain, deformity, or instability after the treatment. The olecranon bone graft was found to be safe and easy to harvest. Its strong tubular structure replaced the distal phalanx successfully.

Keywords: olecranon bone graft, distal phalanx, nonunion

INTRODUCTION

Distal phalangeal fractures are the most common fractures of the hand (Schneider, 1988). Most of them can be successfully treated, either conservatively or surgically. Nonunion, causing pain and deformity, is uncommon after these fractures. Infection, segmental bone loss and associated soft tissue injury, especially neurovascular injury, predispose to nonunions in the distal phalanx (Van Oosterom et al., 2001).

This study presents 11 cases of nonunions of the distal phalanx which were treated with olecranon bone grafting combined with Kirschner wire fixation.

PATIENTS AND METHODS

Eleven patients (ten male, one female) who developed nonunions of the distal phalanx after initial treatment were treated by operation. The mean age was 37.3 (range 26–51) years. Three of the patients had avulsion injuries and eight had crush injuries. The initial injuries of the distal phalanx were: subtotal amputation (six patients); open fracture (three patients); bone defect (one patient); and closed fracture (one patient). The initial injuries were located at the joint level in two patients, at the tuft in two patients and at the shaft of the distal phalanx in eight patients.

In the initial treatments K-wire fixation had been used in all patients. Seven of them underwent nail plate repair,

four patients had nerves repaired, three needed arterial repair and two patients required arthrodesis.

All 11 patients had nonunions after the initial treatment and three of them developed infections. Four of them had bone resorption (with or without infection) that led to the nonunion of the distal phalanx. In the remaining patients inadequate fixation and fixation in a distracted position was found to be the reason for nonunion (Fig 1). These nonunions were located at the arthrodesis site in one patient, at the tuft in two patients and in the shaft of distal phalanx in eight patients. Olecranon bone grafting and K-wire fixation of the distal phalanx were carried out in all patients as a secondary treatment. None of the patients needed soft tissue reconstruction as the soft tissues of the distal phalanx were normal at the time of bone grafting.

The diagnosis of nonunion depends on both clinical and radiological signs. The radiological appearance alone is not sufficient. Fracture lines can be seen radiographically for up to a year with normal clinical healing (Green, 1986; Smith and Rider, 1935). Pain, instability and deformity are important clinical signs of nonunion (Ring, 2005). Jupiter et al. (1985) defined nonunion as the presence of clinical and radiological signs more than 4 months after the initial injury. We believe that this is a reliable period for normal bony healing and the presence of clinical signs for more than 4 months with positive radiological signs deserves intervention.

The diagnosis of nonunion was made by the presence of clinical and radiological signs of nonunion more than

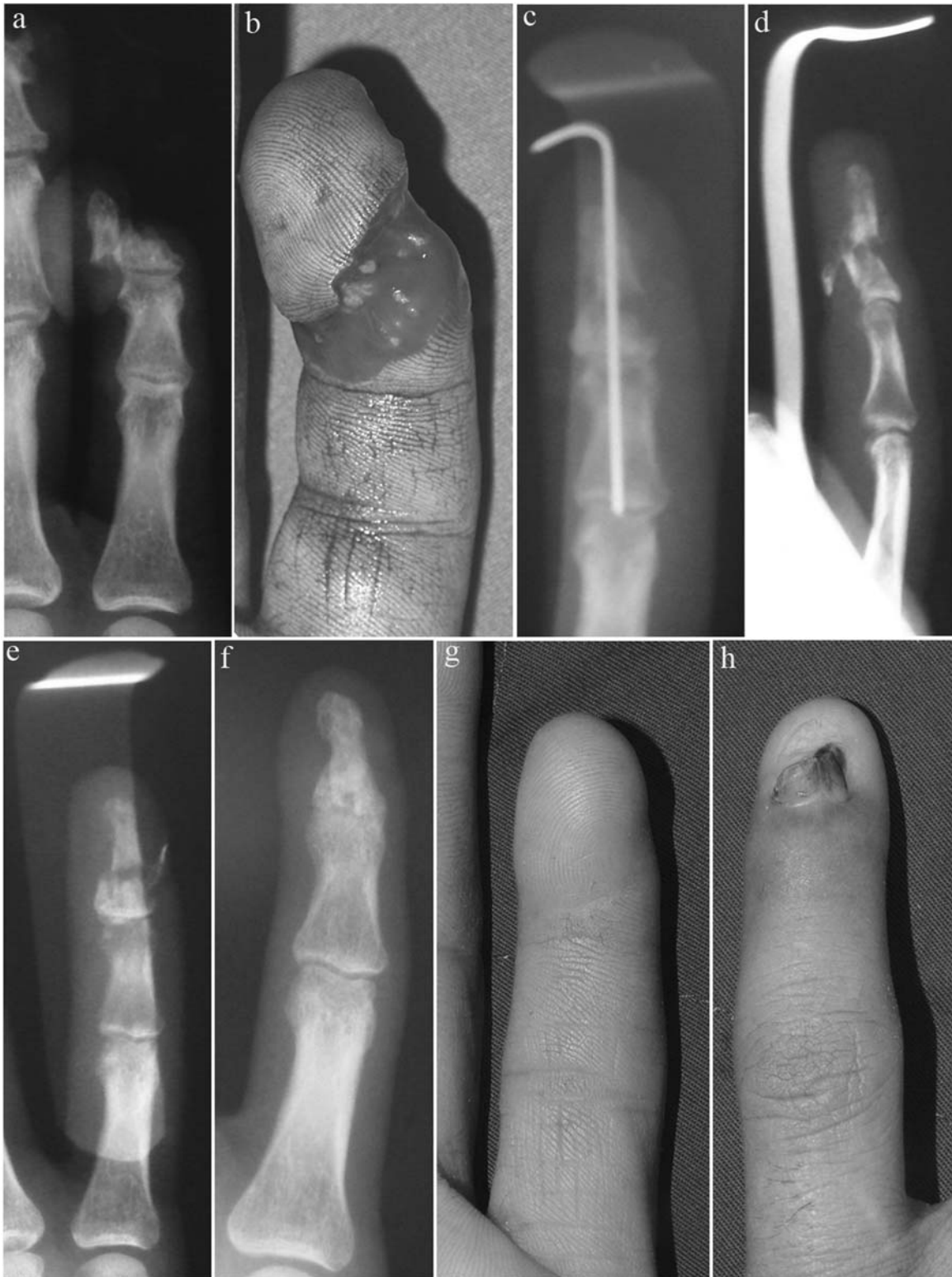

Fig 1 (a, b) Subtotal amputation of little finger. (c) Initial treatment with K-wire fixation in a distracted position which most likely caused nonunion. (d, e) Nonunion at the shaft of the distal phalanx with pain and deformity 5 months after the initial treatment. (f) Seven months after olecranon bone grafting the bony healing was complete. (g) The view of finger pulp after treatment. (h) There was a nail deformity that was probably due to the initial injury and repair.

4 months after the injury. All patients experienced pain and instability and had deformity due to the nonunion of the distal phalanx. The secondary treatments were carried out at least 4 months after initial treatment. However in two patients with obvious bony resorption (defect) after the initial treatment, bone grafting was done before 4 months (Fig 2). Three patients with infection (soft tissue wound infections and pin track infections) were treated by broad-spectrum oral antibiotics and were operated on at least 1 month after the end of antibiotic treatment. The overall mean time delay before the secondary treatment was 4.3 months (range 2–6 months).

Surgical technique

All the patients were operated on under axillary regional anaesthesia. The 3 cm incision for bone graft harvesting was made starting 1.5 cm distal to the tip of the olecranon (Fig 3). The incision was made through the periosteum which was dissected off the bone graft donor site of the olecranon. A rectangular cortical window was removed and preserved to expose the medullary cavity. The cancellous bone graft was harvested by using a fine osteotome. The cortex was replaced and closed after harvesting the graft to prevent a palpable irregularity at the donor site. Cancellous bone grafts were used in all

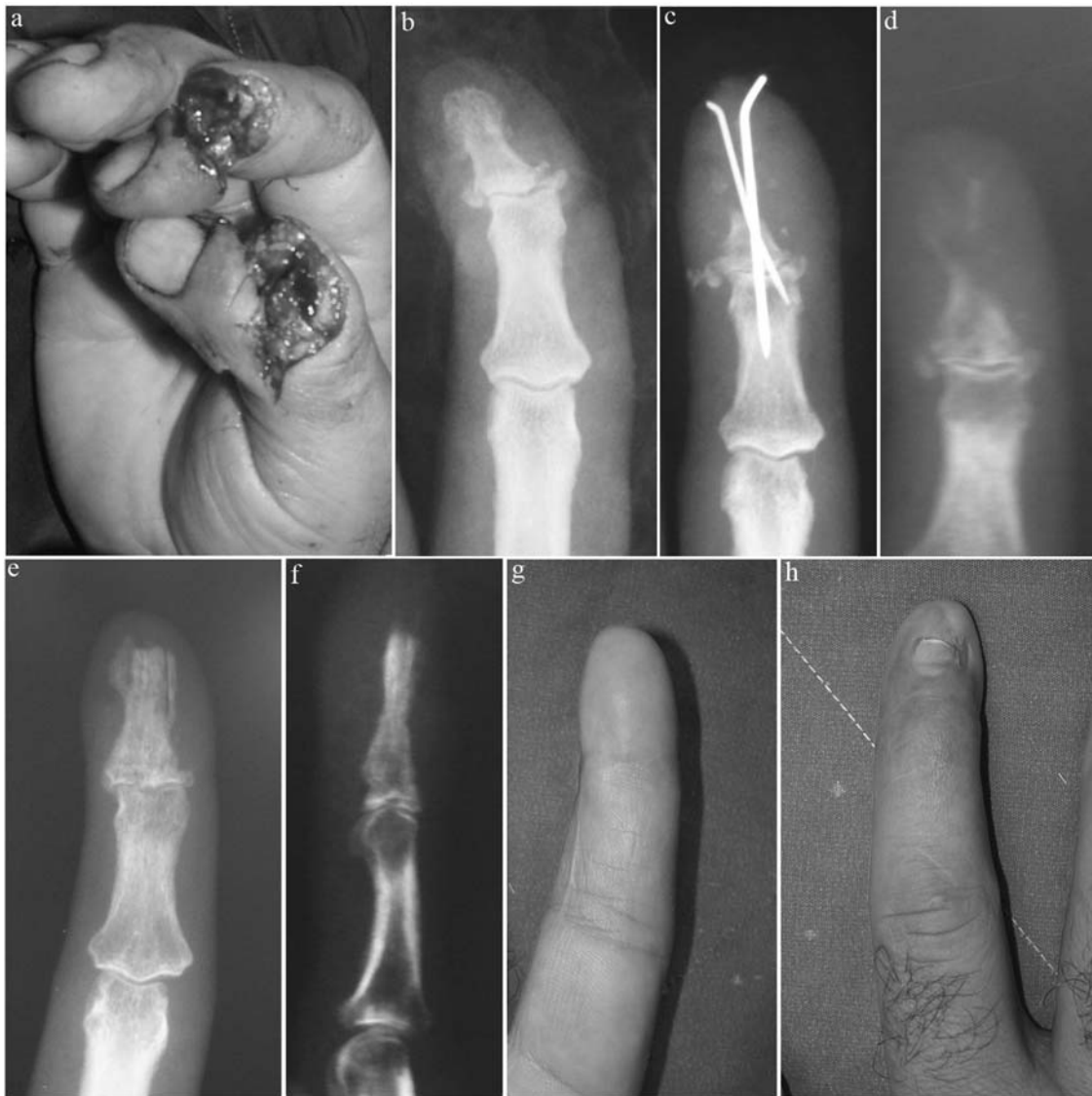

Fig 2 (a) Subtotal amputation of the index finger. (b) Luxation of DIP joint with small intra-articular fractures of the distal phalanx. (c) A pin track infection which caused bone resorption in the shaft of the distal phalanx. (d) The obvious bony defect after control of infection. (e) Anteroposterior view 6 months after successful olecranon bone grafting. (f) The bone graft replaced the distal phalanx successfully. Lateral view. (g, h) The finger pulp and nail 6 months after olecranon bone grafting.

patients and none of them had bone chips or cortico-cancellous grafts. The periosteum and skin were repaired individually. Postoperatively, no cast or splint was used on the elbows and patients were allowed to move the elbow freely.

The recipient site was reached through a unilateral incision made lateral to the nail plate in all patients (Fig 4). The fibrous tissue was excised at the nonunion line exposing the healthy bone edges. The bone graft was adapted and fixed with a K-wire. However, in some patients the bone graft was used to reconstruct the distal phalanx almost totally. A cavity was created in these patients at the defect site and the bone graft was inserted in to the defect and fixed with K-wire. The size of the bone grafts ranged from $18 \times 5 \times 5$ mm to $4 \times 4 \times 4$ mm. The sizes of the K-wires were between 0.8 mm and 1.2 mm. All patients were discharged from the hospital the same day as the operation. They were all given parenteral antibiotics during the hospital stay and continued to take oral antibiotics for 5 days after the operation. The operated finger was splinted for 6 weeks.

Assessment

The patients were checked at postoperative visits for infections of the donor or recipient sites. The K-wires were extracted at the end of the 6-week period after an X-ray examination for bone union. The patients were assessed for pain, deformity, and instability after removal of the K-wires and during the postoperative visits. All patients had a final X-ray taken at least 5 months after bone grafting.

RESULTS

The mean follow up after the secondary treatment was 7 months (range 5–18 months). No major complications

at the recipient site were observed. There were no infections of the bone graft, graft failure, or failure to unite in any patients.

One patient had a haematoma formation at the donor site that subsided after drainage. None of the rest had any complaints about the donor site. There were no fractures, palpable irregularities, pain or discomfort related to the donor sites in any patients.

Ten out of the 11 patients had complete radiological union at the grafted sites. One patient had partial radiological union with complete disappearance of the clinical signs of nonunion. None of them had pain,

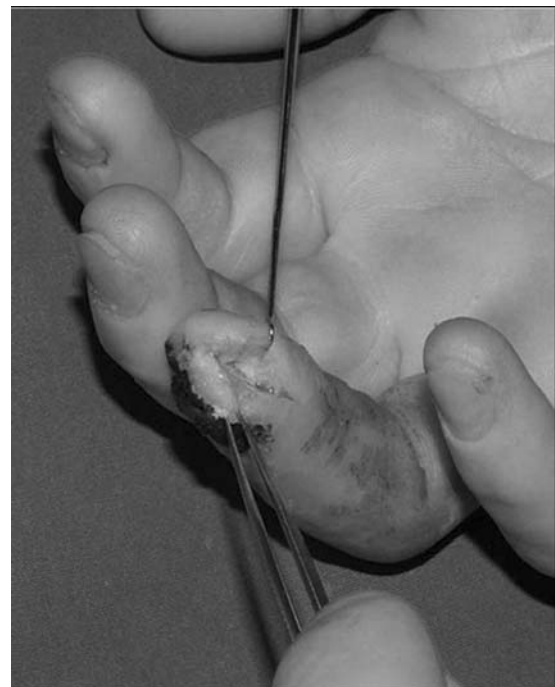

Fig 4 The midlateral incision at the recipient site.

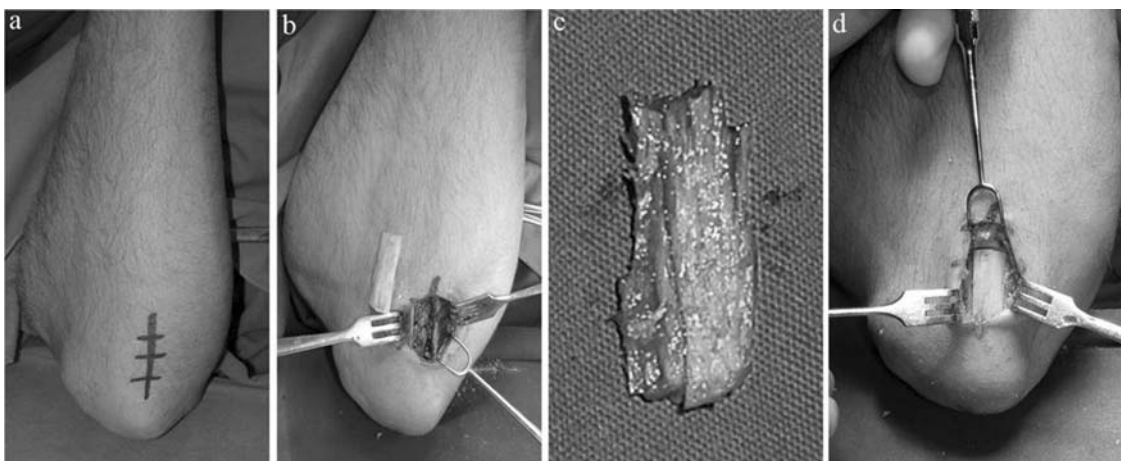


Fig 3 (a) The planned incision for harvesting the olecranon bone graft. (b) A cortical window is opened and preserved. (c) A structured cancellous bone graft has been harvested. (d) The cortex is replaced and the wounds are closed.

deformity, or instability after the treatment. In other words, both radiological and clinical signs of nonunion disappeared after bone grafting.

DISCUSSION

Nonunions are unusual in the phalanx and metacarpals. Barton (1979) reported a 0.7% incidence in fractures of the phalangeal shaft. Borgeskov (1967) reported an incidence of 0.2%. However, Van Oosterom et al. (2001) found that 6% of phalangeal fractures treated surgically resulted in nonunions. These authors felt that the relatively low incidences reported in other studies were because conservatively managed or stable, uncomplicated fractures were included and replantations were excluded.

Most nonunions in the hand are atrophic in type. Hypertrophic and synovial nonunions are unusual (Jupiter et al., 1985). Vascular damage from the initial injury may have been a causative factor in some conservatively treated cases. Infection, segmental bone loss, soft tissue and neurovascular injury are major risk factors in the development of nonunions (Van Oosterom et al., 2001). Associated soft tissue injury devascularises the fracture segments and increases the infection rate and likelihood of nonunion. Devascularising exposures, inadequate fixation and fixation in a distracted position are the major causes of nonunions after operative phalangeal fracture treatment (Ring, 2005).

There are limited reports on the treatment of nonunions in the distal phalanx (Botelho, 1995; Carozzi, 1983; Del Pinal et al., 2006; Itoh et al., 1983; Read, 1982; Richards et al., 1988; Voche et al., 1995). Most of these studies are single case reports. Voche et al. (1995) treated 13 cases of distal phalangeal nonunion, seven of which were bone grafted. Itoh et al. (1983) treated six cases with bone grafting. Jupiter et al. (1985) amputated two of three distal phalangeal nonunions. Vascularised bone blocks from the toe have been used for infected nonunions (Del Pinal et al., 2006) and compression screws alone have also been used in the treatment of distal phalangeal nonunions (Botelho, 1995; Richards et al., 1988).

We recommend that the procedure we have described be done around 4 months after the initial injury in patients with persisting clinical symptoms and radiological signs of nonunion. We believe that 4 months is a reliable period for normal clinical bone healing of the distal phalanx. However in patients with obvious bony defects, the procedure should be done before 4 months. In patients with infection we carried out secondary treatment at least 1 month after the antibiotic treatment and regression of the clinical signs of infection (pain, discharge, and swelling).

We preferred a midlateral incision rather than a midline incision at the finger pulp. We do not think

that a midlateral incision will give an inadequate exposure or will damage important neurovascular structures as Itoh et al. (1983) suggested. On the contrary we had no technical difficulty in carrying out bone grafting of the distal phalanx using a midlateral incision. We believe that making the incision and placing the resultant scar tissue on the lateral side of the distal phalanx is preferable to placing it in the midline of the sensitive finger pulp.

We also believe that the replacement and closure of the cortical window at the donor site prevents palpable irregularity, pain, or discomfort at the donor site.

We find the olecranon bone graft safe and easy to harvest. However, other studies will be needed to compare olecranon bone grafts with distal radius and iliac bone grafts.

References

- Barton NJ. Fractures of the shafts of the phalanges of the hand. *The Hand*. 1979, 11: 119–33.
- Borgeskov S. Conservative treatment of phalangeal and metacarpal fractures. *Ugeskrift for Laeger*. 1967, 129: 349–53.
- Botelho JC. Treatment of pseudoarthrosis of the distal phalanx with a compression screw. *J Hand Surg Br*. 1995, 20: 618–9.
- Carozzi S. Pseudoarthrosis of the fingertip. *Chirurgia Italiana*. 1983, 35: 586–90.
- Del Pinal F, Garcia-Bernal FJ, Delgado J et al. Vascularized bone blocks from the toe phalanx to solve complex intercalated defects in the fingers. *J Hand Surg Am*. 2006, 31: 1075–82.
- Green DP. Complications of phalangeal and metacarpal fractures. *Hand Clin*. 1986, 2: 307–28.
- Itoh Y, Uchinishi K, Oka Y. Treatment of pseudoarthrosis of the distal phalanx with the palmar midline approach. *J Hand Surg Am*. 1983, 8: 80–4.
- Jupiter JB, Koniuch MP, Smith RJ. The management of delayed union and nonunion of the metacarpals and phalanges. *J Hand Surg Am*. 1985, 10: 457–66.
- Read L. Non-union in a fracture of the shaft of the distal phalanx. *The Hand*. 1982, 14: 85–8.
- Richards RR, Khoury G, Young MC. Internal fixation of an unstable open fracture of a distal phalanx with a Herbert screw. *J Hand Surg Am*. 1988, 13: 428–32.
- Ring D. Malunion and nonunion of the metacarpals and phalanges. *J Bone Joint Surg Am*. 2005, 87: 1380–8.
- Schneider LH. Fractures of the distal phalanx. *Hand Clin*. 1988, 4: 537–47.
- Smith FL, Rider DL. A study of the healing of one hundred consecutive phalangeal fractures. *J Bone Joint Surg Am*. 1935, 17: 91–109.
- Van Oosterom FJ, Brete GJ, Ozdemir C, Hovius SE. Treatment of phalangeal fractures in severely injured hands. *J Hand Surg Br*. 2001, 26: 108–11.
- Voche P, Merle M, Pillot D. Pseudoarthrosis and delayed union of the distal phalanx of the long fingers. Apropos of 13 cases. *Rev chir orthop Repatrice Appar Mot*. 1995, 81: 485–90.

Received: 12 April 2007

Accepted after revision: 7 October 2008

Dr. Fatih Kabakas, Deniz Abdal Mah. Millet Cad. Çapa Palas Apt. No:95/1, 34104 Fatih-Istanbul, Turkey. Tel.: +90-532-7381157; fax: +90-212-6331504.

E-mail: fatihkabakas@gmail.com.

doi: 10.1177/1753193409104494 available online at <http://jhs.sagepub.com>