



## Synovial chondromatosis of the metacarpophalangeal joint of the ring finger

İsmail Bülent ÖZÇELİK,\* Samet Vasfi KUVAT,# Berkan MERSA,\* Özgür PİLANCI†

\*İst-Hand Hand Surgery, Microsurgery and Rehabilitation Group Gaziosmanpaşa Hospital, Department of Hand Surgery;

#İstanbul Training and Research Hospital, Department of Plastic and Reconstructive Surgery;

†Bağcılar Training and Research Hospital, Department of Plastic and Reconstructive Surgery; all in İstanbul

Synovial chondromatosis is an uncommon condition, characterized by multinodular cartilaginous proliferation of the joint synovium. There are only a few case reports of synovial chondromatosis involving the hand in the literature. A case of synovial chondromatosis of the ring finger is reported in this paper.

**Key words:** Finger; hand; metacarpophalangeal joint; synovial chondromatosis.

Primary synovial chondromatosis is a benign metaplasia in which synovial tissue transforms into cartilaginous tissue. Primary synovial chondromatosis develops from joint or tendon synovium. Secondary synovial chondromatosis occurs with the implantation of cartilage fragments into the tissue as a result of degenerative disease (osteoarthritis), neuropathic arthropathy, or trauma.<sup>[1,2]</sup> Synovial chondromatosis is twice as common in males, and the most frequent complaints are pain, swelling, and restricted range of motion in the affected joint.<sup>[1]</sup> This condition may present with findings of trigger finger or carpal tunnel syndrome, depending on the location.<sup>[2]</sup> Synovial chondromatosis originating from the joints most commonly affects the knee, hip, and wrist joints, whereas the disease originating from the tendon sheath most frequently involves the feet and the fingers.

Primary synovial chondromatosis originating from the metacarpophalangeal (MCP) joint is rare.<sup>[1]</sup> In this report, we present a patient with synovial

chondromatosis originating from the MCP joint of the ring finger.

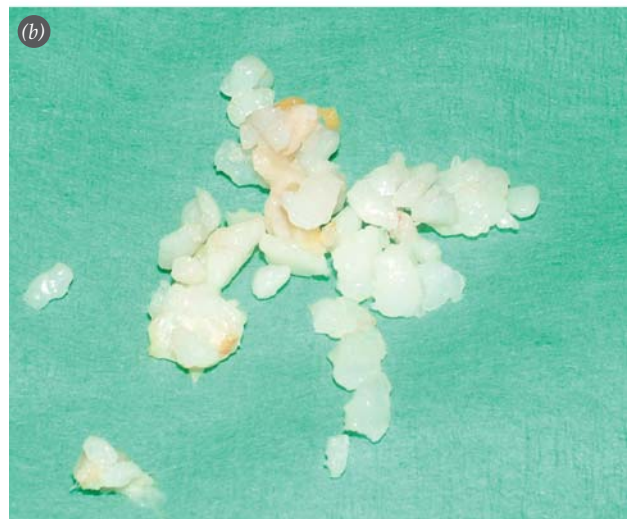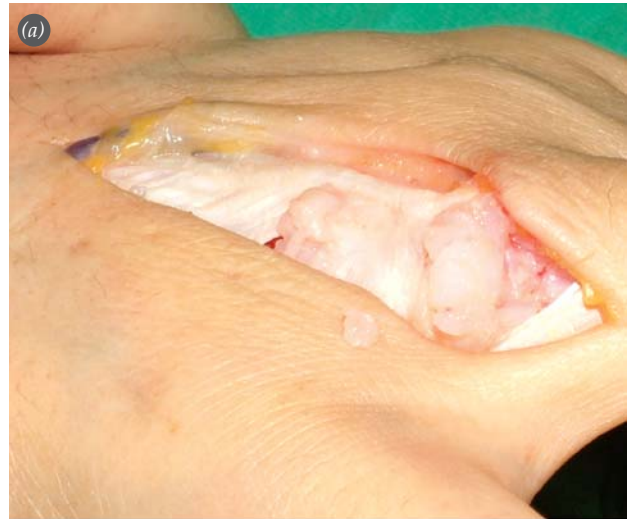### Case report

A 46-year-old woman presented to our clinic with a 2-year history of a progressively enlarging painful mass in her right hand. She did not have a history of trauma, infection, or systemic rheumatologic disease. She was diagnosed with arthritis during the onset of her complaints, and underwent medical treatment. Physical examination revealed a 3x4 cm lobulated mass originating on the extensor surface of the fourth MCP joint, and extending toward the lateral aspect of the ulnar side of the ring finger and the fourth web space. The radiograph of the hand was unremarkable. Magnetic resonance imaging (MRI) showed a mass on the dorsal aspect of the fourth finger extending toward the fourth web space. Histopathology of the excised lesion revealed synovial chondromatosis. There was no recurrence during a two-year follow-up period (Figs. 1-3).

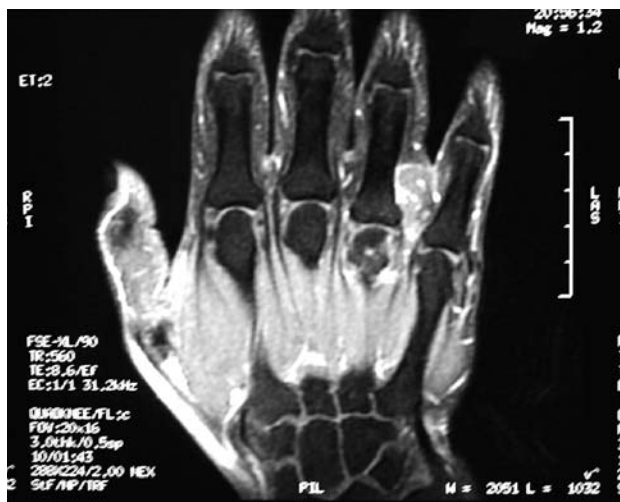**Discussion**

Synovial chondromatosis is a multinodular proliferation of cartilage. Despite confusion in the literature regarding nomenclature, primary synovial chondromatosis describes synovial chondromatosis originating from the joint or tenosynovium.<sup>[3,4]</sup> In the largest synovial chondromatosis series, Fetsch et al.<sup>[3]</sup> named chondromatosis originating from the tenosynovial membrane “tenosynovial” or “extra-articular chondromatosis”.

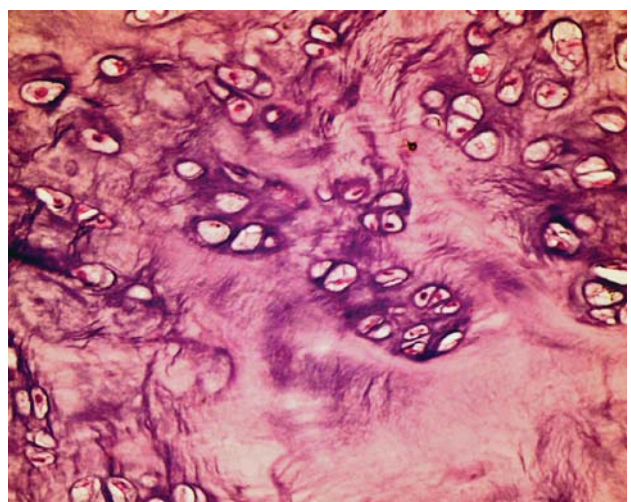
Synovial chondromatosis originating from the joint cartilage or synovium must be differentiated from tenosynovial chondromatosis, and from soft tissue chondroma. Synovial chondromatosis resembles tenosynovial chondromatosis morphologically and histopathologically; however, they differ in pathophysiology because only synovial chondromatosis originates from the joint. They also differ with respect to their location; synovial chondromatosis most often occurs in the knee, hip, and wrist joints, and tenosynovial chondromatosis most often occurs in the tendon sheaths of the hand and foot.<sup>[3]</sup> The primary characteristics of soft tissue chondroma that differentiate it from synovial or tenosynovial chondromatosis are that it is a well circumscribed solitary lesion and that it tends to be seen in younger individuals (ages 10-39 years). The most important difference between the three clinical entities is the rate of recurrence, which is 87.5%,<sup>[3]</sup> 60%, and 20% in tenosynovial chondromatosis, synovial chondro-



**Fig. 2.** (a) Intraoperative view of the lesion, and (b) excised specimen.



**Fig. 1.** Appearance of the lesion on MRI.



**Fig. 3.** Histopathologic view of the specimen (H-E x40).

matosis, and soft tissue chondroma, respectively.<sup>[5]</sup> Therefore, accurate diagnosis is crucial due to the difference in recurrence rates.

Most cases of primary synovial chondromatosis in the hand originate from the tenosynovium, and are located on the flexor aspect of the hand.<sup>[4,6]</sup> Our case has an extensor location, and originates from the MCP joint. The lesion was classified as synovial chondromatosis because of its origin from the joint.

Milgram<sup>[6]</sup> classifies synovial chondromatosis as early, intermediate, or late, depending on the presence of synovial disease and loose bodies. Early stage synovial chondromatosis has only active synovial disease, intermediate stage has active synovial disease and loose bodies, and late stage synovial chondromatosis has only loose bodies.<sup>[4,7]</sup> Our patient had joint pain with no radiologic changes, and therefore, her condition was classified as early-stage synovial chondromatosis.

The diagnosis of synovial chondromatosis is frequently confused with tenosynovitis and arthritis. Normal appearance of the radiograph, and partial improvement in symptoms with antiinflammatory drugs are the most important factors contributing to this confusion.<sup>[2]</sup> Our case was diagnosed with arthritis in the early phase, and was treated conservatively.

The definitive treatment of synovial chondromatosis is surgical excision, which can be carried out endoscopically.<sup>[8]</sup> It should be remembered that the disease has a high recurrence rate, irrespective of the type of surgery performed.

In conclusion, primary synovial chondromatosis should be considered in the differential diagnosis of

patients presenting with pain, mass, or restricted range of motion in the MCP joint.

## References

1. Bui-Mansfield LT, Rohini D, Bagg M. Tenosynovial chondromatosis of the ring finger. *AJR Am J Roentgenol* 2005;184:1223-4.
2. Warme BA, Tigrani DY, Ward CM. Metacarpophalangeal joint synovial osteochondromatosis: a case report. *Iowa Orthop J* 2008;28:91-3.
3. Fetsch JF, Vinh TN, Remotti F, Walker EA, Murphey MD, Sweet DE. Tenosynovial (extraarticular) chondromatosis: an analysis of 37 cases of an underrecognized clinicopathologic entity with a strong predilection for the hands and feet and a high local recurrence rate. *Am J Surg Pathol* 2003;27:1260-8.
4. Ueo T, Kashima K, Daa T, Kashima N, Tsuji K, Hisaoka M, Yokoyama S. A case of tenosynovial chondromatosis with tophus-like deposits. *APMIS* 2004;112:624-8.
5. Kleihues P, Sobin LH. Synovial chondromatosis. In: Fletcher CDM, Unni KK, Mertens F, editors. *World Health Organization classification of tumours. Pathology and genetics of tumours of soft tissue and bone*. Lyon: IARC; 2002. p. 246.
6. Milgram JW. Synovial osteochondromatosis: a histopathological study of thirty cases. *J Bone Joint Surg Am* 1977; 59:792-801.
7. Gil-Albarova J, Morales-Andaluz J, Castiella T, Seral F. Tenosynovial chondromatosis of the third finger. *Arch Orthop Trauma Surg* 2000;120:239-40.
8. Bilgin SS, Köse KC, Adıyaman S, Demirtaş M. Early functional results of arthroscopic surgery for ankle lesions. [Article in Turkish] *Acta Orthop Traumatol Turc* 2004;38: 23-9.